

# Cone-beam computed tomography-based radiographic considerations in impacted lower third molars: Think outside the box

Ali Fahd<sup>1,\*</sup>, Ahmed Talaat Temerek<sup>2</sup>, Mohamed T. Ellabban<sup>3</sup>, Samar Ahmed Nouby Adam<sup>4</sup>, Sarah Diaa Abd El-wahab Shaheen<sup>5</sup>, Mervat S. Refai<sup>6</sup>, Zein Abdou Shatat<sup>7</sup>

<sup>1</sup>Department of Oral and Maxillofacial Radiology, Faculty of Oral and Dental Medicine, Egyptian Russian University, Cairo, Egypt

<sup>2</sup>Department of Oral and Maxillofacial Surgery, Faculty of Oral and Dental Medicine, South Valley University, Qena, Egypt

<sup>3</sup>Department of Orthodontics and Dentofacial Orthopedics, Faculty of Dentistry, Assiut University, Assiut, Egypt

<sup>4</sup>Department of Periodontology and Oral Medicine, Faculty of Oral and Dental Medicine, South Valley University, Qena, Egypt

<sup>5</sup>Department of Operative Dentistry, Sinai University, Kantara, Egypt

<sup>6</sup>Department of Oral and Maxillofacial Surgery, Ministry of Interior Hospitals, Cairo, Egypt

<sup>7</sup>Department of Oral and Maxillofacial Radiology, Faculty of Dentistry, Assiut University, Assiut, Egypt

## ABSTRACT

**Purpose:** This study aimed to evaluate the anatomic circle around the impacted lower third molar to show, document, and correlate essential findings that should be included in the routine radiographic assessment protocol as clinically meaningful factors in overall case evaluation and treatment planning.

**Materials and Methods:** Cone-beam computed tomographic images of impacted lower third molars were selected according to specific inclusion criteria. Impacted teeth were classified according to their position before assessment. The adjacent second molars were assessed for distal caries, distal bone loss, and root resorption. The fourth finding was the presence of a retromolar canal distal to the impaction. Communication with the dentist responsible for each case was done to determine whether these findings were detected or undetected by them before communication.

**Results:** Statistically significant correlations were found between impaction position, distal bone loss, and detected distal caries associated with the adjacent second molar. The greatest percentage of undetected findings was found in the evaluation of distal bone status, followed by missed detection of the retromolar canal.

**Conclusion:** The radiographic assessment protocol for impacted third molars should consider a step-by-step evaluation for second molars, and clinicians should be aware of the high prevalence of second molar affection in horizontal and mesioangular impactions. They also should search for the retromolar canal due to its associated clinical considerations. (*Imaging Sci Dent* 20220191)

**KEY WORDS:** Alveolar Bone Loss; Dental Caries; Mandibular Canal; Root Resorption; Cone-Beam Computed Tomography

## Introduction

Third molar impaction is a common problem associated with economic and personal costs.<sup>1,2</sup> The patient's quality of life is affected either by the impacted tooth itself or its associated effects on adjacent structures, such as periodontal involvement, root resorption, and dental caries.<sup>3</sup> Management

protocols should be based on a proper understanding of scientific evidence, guidelines, and proper overall case examination.<sup>4</sup>

Distal caries in the second molar adjacent to impaction may cause pain due to pulpitis or apical periodontitis, which should be considered during treatment planning for the impacted tooth.<sup>5,6</sup> Impacted third molars are also the leading cause of marginal bone loss, the presence of periodontal pocket, and root involvement on the distal aspect of the adjacent second molar, which can lead to pain, discomfort, or even tooth loss in some cases of impaction.<sup>7</sup>

Cone-beam computed tomography (CBCT) is a useful

Received October 29, 2022; Revised February 9, 2023; Accepted February 27, 2023  
Published online April 15, 2023

\*Correspondence to : Assistant Prof. Ali Fahd

Department of Oral and Maxillofacial Radiology, Faculty of Oral and Dental Medicine, Egyptian Russian University, Cairo 11829, Egypt  
Tel) 20-100-5364733, E-mail) Dr.ali.fahd.dentist@gmail.com

Copyright © 2023 by Korean Academy of Oral and Maxillofacial Radiology

This is an Open Access article distributed under the terms of the Creative Commons Attribution Non-Commercial License (<http://creativecommons.org/licenses/by-nc/3.0>) which permits unrestricted non-commercial use, distribution, and reproduction in any medium, provided the original work is properly cited.

Imaging Science in Dentistry · pISSN 2233-7822 eISSN 2233-7830

3-dimensional imaging modality that provides the clinician with detailed information about the impacted tooth and surrounding tissues. These data should be carefully interpreted for proper case analysis and decision-making.<sup>8</sup>

CBCT imaging for an impacted third molar usually reveals information about the adjacent second molar anteriorly and the retromolar area posteriorly. The retromolar area should be included in the radiographic interpretation protocol for the clinical consideration of anatomical variations during the intended surgery or as a common proposed donor site for any future autogenous bone grafting.<sup>9,10</sup> Radiographic detection of the retromolar canal and its foramen is vital for the surgeon to administer local anesthesia and to avoid complications such as bleeding or postoperative altered local sensation.<sup>11,12</sup>

This retrospective CBCT-based study evaluated the anatomic circle around the impacted lower third molar. The aim was to show, document, and correlate significant radiographic findings, other than those related to the impacted tooth itself, that should be clinically considered in the overall case evaluation and treatment planning to provide a patient-relevant intervention.

## Materials and Methods

This study was approved by the institute's ethical review board (code: SVUFODM-OMS-4-22-9-450). CBCT images acquired by the Planmeca Promax 3D Classic machine (Planmeca Oy, Helsinki, Finland) with operating parameters of 90 kVp, 6 mA, voxel size of 0.2 mm, and a field of view (FOV) including the impacted lower third molar were retrospectively used in this study if fulfilling the following inclusion criteria: 1) displaying the second molar and the mesial part of the first molar area, 2) displaying the retromolar area,

3) the upper and lower arches were separated by a cotton roll, 4) no artifacts obscured the region of interest (ROI), and 5) no lesions were present on the same side.

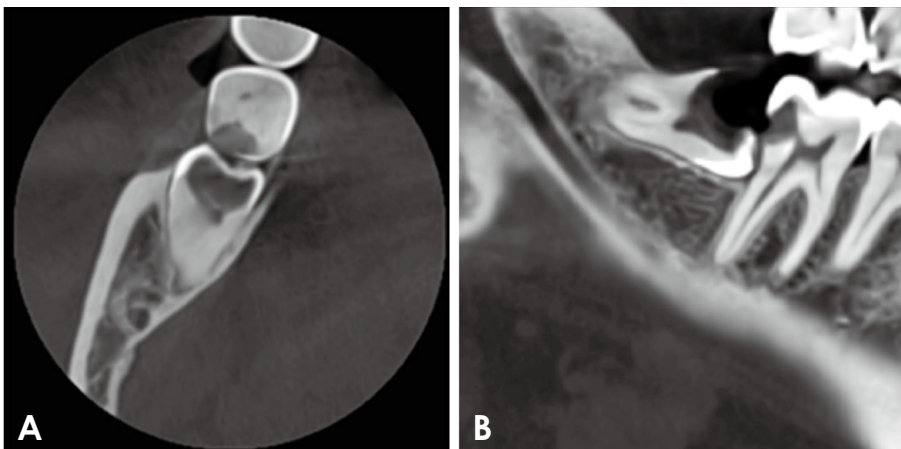
Initially, the protocol used by Li et al.<sup>13</sup> was adopted for impaction angulation (distoangular, vertical, mesioangular, horizontal, and others); thus, impaction was classified according to position for correlation with other findings.

Three of the four findings that were included in this study were related to the adjacent second molar - namely, distal caries (DC), distal bone loss (BL), and root resorption (RR) - while the fourth studied finding was the presence of retromolar canal and foramen (RMC) distal to impaction.

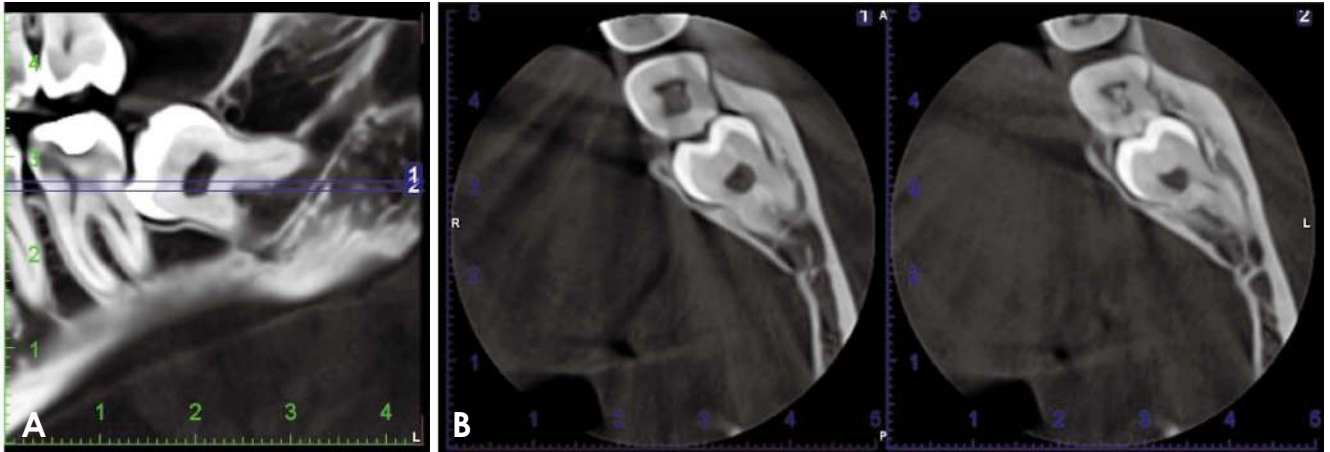
The first protocol was for caries detection. Caries in the proximal-distal surface in the adjacent second molar were detected by navigation through axial slices of 0.2-mm slice thickness (Fig. 1A). It was marked as "yes" for positive detection (radiolucent spot or area) or "no" for negative findings after confirmation with the sliced reformatting panorama-like view of 1-mm slice thickness (Fig. 1B).

Another protocol was used to detect second molar distal root resorption based on navigation in the sliced reformatting panorama-like view of 1-mm slice thickness. Navigation was done until the area of contact or maximum approximation between the third molar crown and the second molar distal root was found (Fig. 2A). Suspected affection was examined in the axial cuts (Fig. 2B) at the same level of contact or approximation as confirmed by the axial reference lines before being classified as "yes" (deficient or concave outer surface) or "no" for negative findings.

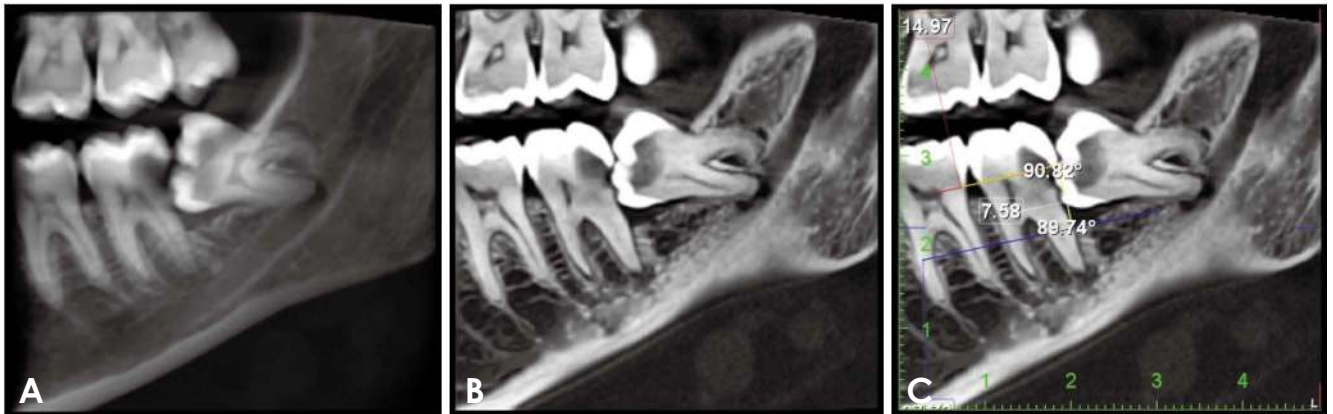
For distal periodontal bone loss in relation to the second molar (Fig. 3A), a ruler was used to measure the bone level from the cemento-enamel junction or its level to the superior crestal bone level contacting the distal root; this was done in the sliced panorama-like view with 1-mm slice



**Fig. 1.** A. Axial cut shows distal caries in the adjacent second molar. B. A 1-mm-sliced reformatting panorama-like view confirms the finding and shows the caries depth. The intact occlusal surface may hide caries clinically, as well as the depth of caries, which may be the cause of the pain.



**Fig. 2.** A. Identification of the area of contact or pressure between the second and third molars in a 1-mm-sliced reformatted panorama-like view. B. Detection and confirmation of resorption on axial slices of the same level. The third molar root should be noted in relation to the inferior alveolar canal and the distal bone loss related to the second molar.



**Fig. 3.** A. Reformatted panorama-like view shows distal bone loss. B. A 1-mm-sliced reformatted panorama-like view on which the protocol is carried out. C. The standardization protocol for bone level measurements.

thickness (Fig. 3B).

To standardize the measurements, a red color-coded reference line was drawn connecting the cemento-enamel junctions of the adjacent molars using the measurement tool (ruler). A second blue reference line was drawn at the same level as the first reference line and matched with it except for being more prominent in the mesiodistal dimension for ease of differentiation and then dragged in the apical direction to be tangent with the first point of contact between the bone and root at the distal side of the second molar (Fig. 3C).

A white measurement line was drawn connecting the red and blue lines and perpendicular to both. Two angular measurements were done to ensure that the white line was perpendicular to the other reference lines. Angles of  $90^\circ \pm 2^\circ$  were accepted (Fig. 3C); otherwise, the line was adjusted

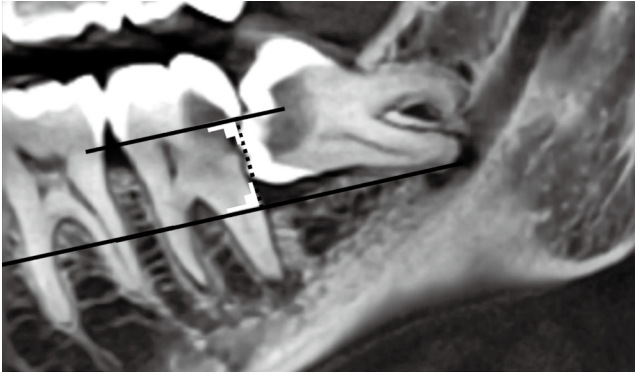
or redrawn. A clear illustration of the lines is shown in Fig. 4.

The results of measurements of the white line were classified as normal (less than 3 mm), mild (3-4 mm), moderate (4.1-6 mm), and severe (more than 6 mm) bone loss, as quantified in the study of Dias et al.<sup>14</sup>

The last finding in this study was the presence or absence of the retromolar canal (Figs. 5 and 6), which was detected by navigation through a 1-mm thickness sliced reformatted panorama-like view and confirmed by cross-sectional and axial cuts. This protocol was proposed to show hidden canals (Fig. 5).

Communication with doctors responsible for each case was done to determine whether they had detected those findings before communication. An enhanced 3-dimensional (3D) model was sent to each doctor to increase their





**Fig. 4.** A clear illustration of the lines and angles used for periodontal assessment.

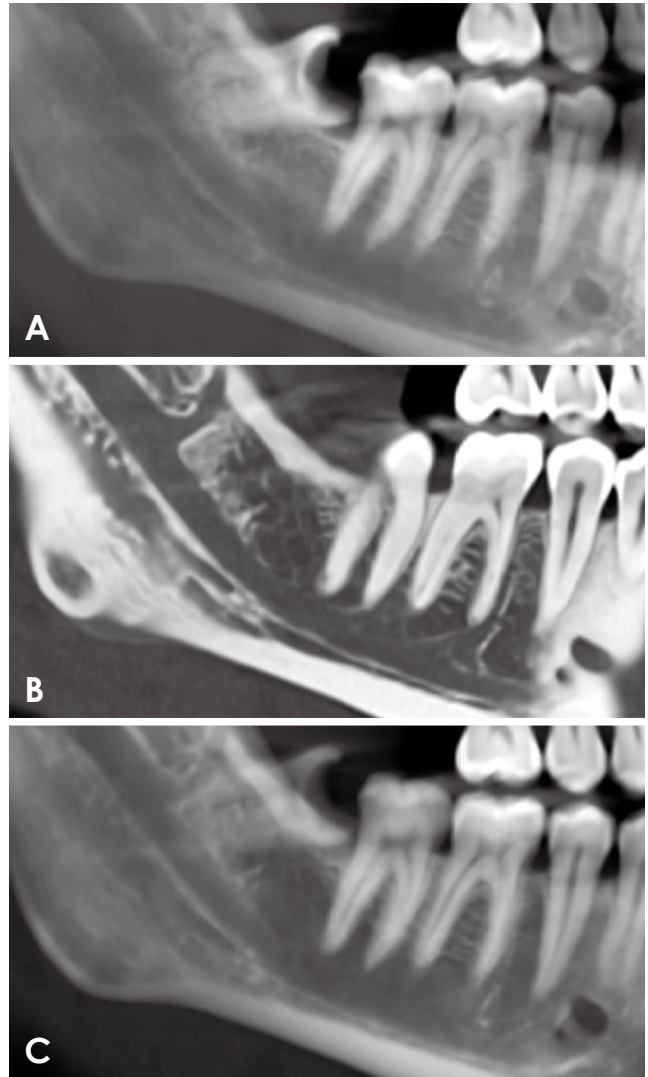
compliance. The enhanced model can be used for effective patient communication and education (Fig. 6).

Enhancement was done by using the cleaning tool found in the same system software (Planmeca Romexis 5.3 - Planmeca Oy, Helsinki, Finland). The outer surface noise and unneeded areas (as opposing teeth) found in the modified black-and-white volume rendering style were removed before going back to the default volume style (Fig. 6). The volume rendering parameters were modified by increasing the transparency to the maximum and decreasing the contrast to the minimum.

Data were explored for the normality of their distribution using Shapiro-Wilk tests. For non-parametric data, the Spearman rank correlation coefficient was used to evaluate the correlations between variables. The significance level was set at  $P < 0.05$ . According to Dancey and Reidy's categorization of correlations,<sup>15</sup> the strength of the correlation and the value of the correlation coefficient were interpreted as follows: a) perfect: 1, b) strong: 0.70 to 0.90, c) moderate: 0.40 to 0.60, d) weak: 0.10 to 0.30, and e) no correlation: less than 0.10. Statistical analysis was performed with IBM SPSS Statistics version 22 for Windows (IBM Corp, Armonk, NY, USA).

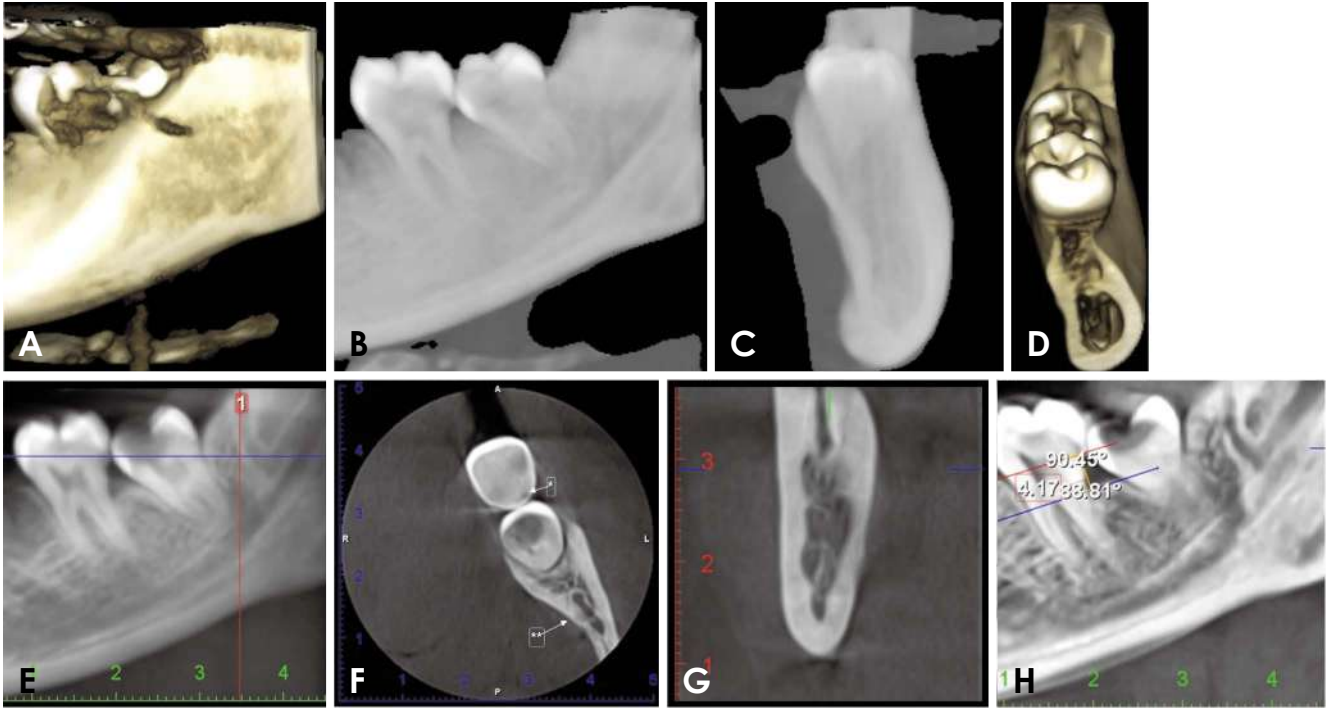
## Results

Eighty-four CBCT images were retrieved to be matched with the inclusion criteria. One case showed a lingually positioned crown of the third molar and was excluded from the study because it was the only case in that position. All other cases were distoangular, vertical, mesioangular, or horizontal. The Shapiro-Wilk test showed that data were non-parametric, so Spearman rank correlation coefficients were used to evaluate the correlations between variables.



**Fig. 5.** A. Full-thickness reformatted panorama-like view with a hidden retromolar canal. B. A 1-mm-sliced reformatted panorama-like view clearly shows the retromolar canal. C. A medium-thickness reformatted panorama-like view clearly shows the retromolar canal and its approximation to the shadow of the distal root of impaction.

The Spearman rank correlation coefficient test revealed a statistically significant correlation between the impaction position of the third molar and the bone level and distal caries of the second molar. This correlation was strong to medium between the impaction position and the bone level of the second molar. Horizontal impaction was associated with more bone loss, followed in order by mesioangular impaction and vertical impaction, while distoangular impaction was associated with a normal bone level. The correlation between the impaction position and the presence of distal caries of the second molar was moderate to weak; specifically, horizontal impaction was associated with more



**Fig. 6.** A. Three-dimensional volume before enhancement. B. Modified black-and-white rendering in which the noise is identified to be cleaned. C. Cleaning from different perspectives. D. Three-dimensional volume after enhancement shows the retromolar canal for effective patient communication. E. Reformatted panoramic image with axial and cross-sectional reference lines. F. Axial slice shows the distal caries spot in the adjacent tooth (note the shape of the canals in the axial slice). G. Cross-sectional slice shows the retromolar canal. H. Sliced reformatted panorama shows the measurements of periodontal bone level.

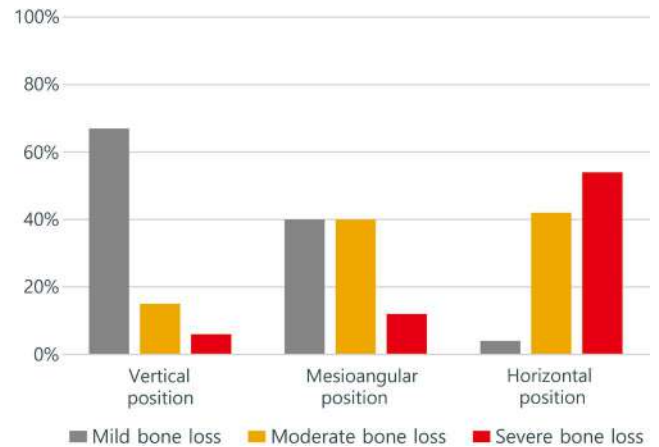
**Table 1.** Spearman correlation coefficients for the relationships between the position of impaction and bone level, distal caries of the second molar, retromolar canal, and root resorption

	Bone level	Distal caries	Retromolar canal	Root resorption
Position of impaction	0.676*	0.301*	0.092	0.104

\*: significant correlation ( $P < 0.05$ )

caries in the adjacent second molar, followed in order by mesioangular impaction and vertical impaction, while distoangular impaction showed no association with caries of the second molar (Table 1). A non-statistically significant correlation was found between the impaction position with the retromolar canal and root resorption.

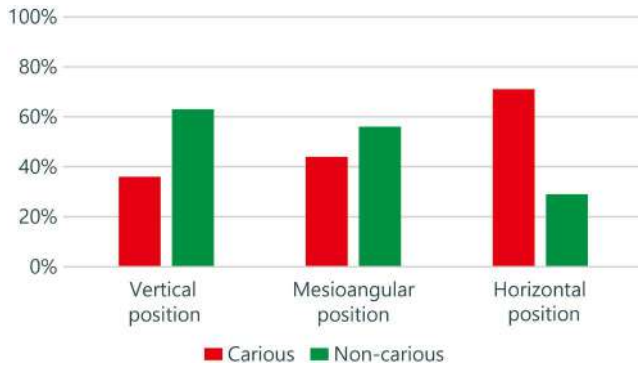
A descriptive analysis of data (Figs. 7 to 9) revealed that all distoangular impaction cases had normal bone levels, while 12% of vertical impaction cases had normal bone levels, 67% had mild bone loss, 15% had moderate bone loss, and only 6% had severe bone loss. Furthermore, 8% of the mesioangular impaction cases had normal bone levels, 40% had mild bone loss, 40% had moderate bone



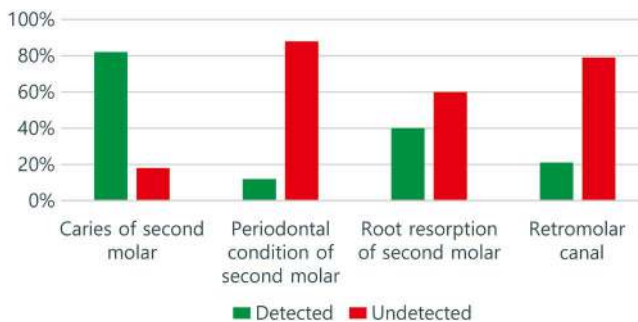
**Fig. 7.** Status of distal bone in relation to each impaction position.

loss, and 12% had severe bone loss. Severe bone loss was significantly associated with horizontal impaction (54% of cases); furthermore, 42% of horizontal impaction cases had moderate bone loss, and only 4% had mild bone loss (Fig. 7).

Regarding the detection of caries in the second molar in each impaction category, horizontal impaction showed the



**Fig. 8.** Radiographically detected dental caries in relation to each impaction position.



**Fig. 9.** The percentage of detected and undetected (missed) findings of each factor by clinicians.

highest percentage (71%), while distoangular impaction showed the lowest percentage, with no caries in the second molars (Fig. 8).

The highest percentage of undetected findings was found in the evaluation of distal bone status regarding the adjacent second molar, followed by the missed finding of the retromolar canal (Fig. 9).

## Discussion

All of the anatomical structures found in a CBCT scan should be evaluated carefully for any radiographic findings with clinical implications to provide patient-tailored treatment planning. Thus, the motivation for this study was to increase awareness of the importance of a systematic interpretation.

Choosing images showing the mesial side of the first molar helped to show the second molar distal side with high quality due to the absence of noise inside the field rather than in the periphery.<sup>16</sup> This field of view was also helpful in standardizing the periodontal assessment protocol by guaranteeing the presence of a reference for the drawing

cemento-enamel junction level. If the distal cemento-enamel junction of the second molar is undetected due to caries, a reference line can be drawn depending on the cemento-enamel junction of the first molar, and then extending the line to the area of interest passing through the mesial aspect of the second molar.

Syed et al.<sup>17</sup> stated that the presence of impaction and its angle increases the risk of distal caries in the adjacent tooth, and they detected caries in 39% of second molars adjacent to impaction. In our study, the percentage was higher (47.6%), which may be because we used CBCT rather than the panoramic radiography used in their study. Although caries were not hard to detect on CBCT slices, clinicians did not detect 17.5% of cases with positive caries. This may have been because clinicians were not searching for caries, especially initial caries lesions.

In the study of Raheem et al.,<sup>18</sup> the highest prevalence of caries was found with horizontally impacted teeth, while Syed et al.<sup>17</sup> showed that the highest prevalence was related to mesioangular impaction. In our study, the highest prevalence was found in cases of horizontal impaction, followed by mesioangular impaction, which guides the clinicians to the importance of a thorough examination for caries in these cases.

Regarding periodontal involvement, Yesiltepe and Kılıcı<sup>19</sup> reported that marginal bone loss was found in the distal side of the second molar teeth in the majority of cases, regardless of the position of the adjacent impaction. Others reported that the prevalence of distal marginal bone loss in second molars increased in cases of mesioangular and horizontally impacted third molars.<sup>20</sup> In the present study, there was a significant correlation between impaction and distal bone loss, and this correlation was medium-to-strong regarding horizontal impaction, followed by mesioangular impaction.

The results of this study correlating the horizontal and mesioangular position of impaction with a high likelihood of damaging effects on adjacent second molars match the studies of Matzen et al.<sup>21</sup> and Orhan et al.,<sup>22</sup> who found that these positions were highly predictive for pathology. The present findings raise the question of whether prophylactic surgery for the impacted lower third molar in these cases may be recommended to save the second molar from irreversible damage.

Another critical point is external root resorption. Communication with the clinicians showed that 3 out of the 5 cases (60%) were previously undetected. It is worth mentioning that the root resorption prevalence was as high as 22.88% of cases in the study of Oenning et al.,<sup>23</sup> and root

resorption was more related to impaction with mesioangular and horizontal contact. In the study of Orhan et al.,<sup>22</sup> detected root resorption of second molars was significantly correlated with horizontal impaction.

In this study, the prevalence of the retromolar canal and related retromolar foramen was 16.6%, which is close to the findings of Alves and Deana,<sup>24</sup> who detected a percentage of 18% using dry mandibles and periapical radiography. Bilecenoglu and Tuncer<sup>11</sup> detected a percentage of 25% and reported other studies with a range from as low as 1.7% to as high as 72%. These different results for prevalence may be due to studying different populations in different geographic areas, which shows the importance of this study in documenting prevalence in this population.

A prevalence of 16.6% was found in this study; furthermore, 11 of the 14 cases (78.5%) were undetected by the clinicians, which showed how important it is to recommend a careful examination of the retromolar area during treatment planning for impaction surgery regarding factors such as anesthesia, flap design and retraction, bleeding, and other complications.<sup>25</sup> It is also recommended to inform patients of these findings through an enhanced 3D volume and document them in patients' medical records for clinical consideration in any future surgery involving this site.

In conclusion, the present study highlighted the importance of the step-by-step use of CBCT in cases of impacted third molars. Our findings showed a medium to strong correlation between the position of the impacted mandibular third molar and bone loss in relation to the adjacent second molar. This bone loss was frequently undetected by clinicians during their routine CBCT inspections. Moreover, a weak to moderate correlation was found between the position of the impacted third molar and the distal caries of the adjacent second molar, which is important to consider during treatment planning. This study also highlighted one of the advantages of navigation through a 1-mm-sliced reformatted panoramic-like view in all cases of impaction.

**Conflicts of Interest:** None

## References

1. Carter K, Worthington S. Morphologic and demographic predictors of third molar agenesis: a systematic review and meta-analysis. *J Dent Res* 2015; 94: 886-94.
2. Ghaeminia H, Nienhuijs ME, Toedtling V, Perry J, Tummers M, Hoppenreijts TJ, et al. Surgical removal versus retention for the management of asymptomatic disease-free impacted wisdom teeth. *Cochrane Database Syst Rev* 2020; 5: CD003879.
3. Al-Khateeb TH, Bataineh AB. Pathology associated with impacted mandibular third molars in a group of Jordanians. *J Oral Maxillofac Surg* 2006; 64: 1598-602.
4. Hyam DM. The contemporary management of third molars. *Aust Dent J* 2018; 63 Suppl 1: S19-26.
5. Kang F, Huang C, Sah MK, Jiang B. Effect of eruption status of the mandibular third molar on distal caries in the adjacent second molar. *J Oral Maxillofac Surg* 2016; 74: 684-92.
6. Chen Y, Zheng J, Li D, Huang Z, Huang Z, Wang X, et al. Three-dimensional position of mandibular third molars and its association with distal caries in mandibular second molars: a cone beam computed tomographic study. *Clin Oral Investig* 2020; 24: 3265-73.
7. Hermann L, Wenzel A, Schropp L, Matzen LH. Marginal bone loss and resorption of second molars related to maxillary third molars in panoramic images compared with CBCT. *Dentomaxillofac Radiol* 2019; 48: 20180313.
8. Matzen LH, Wenzel A. Efficacy of CBCT for assessment of impacted mandibular third molars: a review - based on a hierarchical model of evidence. *Dentomaxillofac Radiol* 2015; 44: 20140189.
9. Sanz-Sánchez I, Ortiz-Vigón A, Sanz-Martín I, Figuero E, Sanz M. Effectiveness of lateral bone augmentation on the alveolar crest dimension: a systematic review and meta-analysis. *J Dent Res* 2015; 94 (9 Suppl): 128S-42S.
10. Parvini P, Sader R, Sahin D, Becker J, Schwarz F. Radiographic outcomes following lateral alveolar ridge augmentation using autogenous tooth roots. *Int J Implant Dent* 2018; 4: 31.
11. Bilecenoglu B, Tuncer N. Clinical and anatomical study of retromolar foramen and canal. *J Oral Maxillofac Surg* 2006; 64: 1493-7.
12. Naitoh M, Nakahara K, Suenaga Y, Gotoh K, Kondo S, Arijji E. Comparison between cone-beam and multislice computed tomography depicting mandibular neurovascular canal structures. *Oral Surg Oral Med Oral Pathol Oral Radiol Endod* 2010; 109: e25-31.
13. Li D, Tao Y, Cui M, Zhang W, Zhang X, Hu X. External root resorption in maxillary and mandibular second molars associated with impacted third molars: a cone-beam computed tomographic study. *Clin Oral Investig* 2019; 23: 4195-203.
14. Dias MJ, Franco A, Junqueira JL, Fayad FT, Pereira PH, Oenning AC. Marginal bone loss in the second molar related to impacted mandibular third molars: comparison between panoramic images and cone beam computed tomography. *Med Oral Patol Oral Cir Bucal* 2020; 25: e395-402.
15. Dancey CP, Reidy J. Statistics without maths for psychology. 7 ed. Pearson: London; 2022.
16. Santaella GM, Rosalen PL, Queiroz PM, Haiter-Neto F, Wenzel A, Spin-Neto R. Quantitative assessment of variation in CBCT image technical parameters related to CBCT detector lateral-offset position. *Dentomaxillofac Radiol* 2020; 49: 20190077.
17. Syed KB, Alshahrani FS, Alabsi WS, Alqahtani ZA, Hameed MS, Mustafa AB, et al. Prevalence of distal caries in mandibular second molar due to impacted third molar. *J Clin Diagn Res* 2017; 11: ZC28-30.
18. Raheem AA, Alhamdani F, Kamal B. The influence of mandibular third molar position on distal caries in mandibular second molar. *J Oral Dent Res* 2015; 2: 16-23.
19. Yesiltepe S, Kılıcı G. Evaluation the relationship between the

- position and impaction level of the impacted maxillary third molar teeth and marginal bone loss, caries and resorption findings of the second molar teeth with CBCT scans. *Oral Radiol* 2022; 38: 269-77.
20. Altan A, Akbulut N. Does the angulation of an impacted mandibular third molar affect the prevalence of preoperative pathoses? *J Dent (Shiraz)* 2019; 20: 48-52.
  21. Matzen LH, Schropp L, Spin-Neto R, Wenzel A. Radiographic signs of pathology determining removal of an impacted mandibular third molar assessed in a panoramic image or CBCT. *Dentomaxillofac Radiol* 2017; 46: 20160330.
  22. Orhan BK, Yılmaz D, Ozemre MO, Kamburoğlu K, Gulen O, Gulsahi A. Evaluation of mandibular third molar region in a turkish population using cone-beam computed tomography. *Curr Med Imaging* 2020; 16: 1105-10.
  23. Oenning AC, Neves FS, Alencar PN, Prado RF, Groppo FC, Haiter-Neto F. External root resorption of the second molar associated with third molar impaction: comparison of panoramic radiography and cone beam computed tomography. *J Oral Maxillofac Surg* 2014; 72: 1444-55.
  24. Alves N, Deana NF. Anatomical and radiographical study of the retromolar canal and retromolar foramen in macerated mandibles. *Int J Clin Exp Med* 2015; 8: 4292-96.
  25. Truong MK, He P, Adeeb N, Oskouian RJ, Tubbs RS, Iwanaga J. Clinical anatomy and significance of the retromolar foramina and their canals: a literature review. *Cureus* 2017; 9: e1781.